



Ophthalmic
Imaging
Association

Sponsored by



Photographic Competition 2010

6 Categories

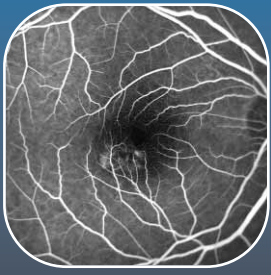6 Winners

1 **Overall Winner** will win an all expenses trip to the OPS Annual Meeting in Orlando, Florida in October 2011

Will you be here in 2011?



Some of the 2009 winning images



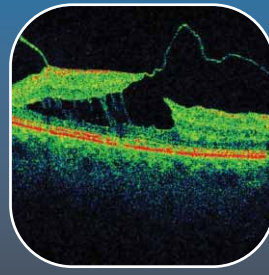
Best FFA Image
by Richard Hancock



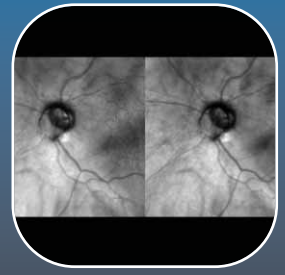
Best Artistic Image
by Jon Brett



Best Anterior
Segment Image
by Abi Loose



Best OCT Image
by Rebecca Lunn



Best Fundus Image
by Stephen Connell

Competition Rules

All images submitted should be clearly labelled with the category for which it is to be considered. Entries used in previous years can not be submitted again.

All entries must be submitted on high quality photographic paper with the candidates name, hospital and entry category clearly noted on the reverse. Electronic images submitted will be disqualified. Only one submission per category per entrant. There should be no patient identifying information on the image.

All submissions will be judged on the degree of photographic skill necessary to obtain the image, degree of difficulty, overall quality and complexity.

It is the entrant's responsibility to ensure they have obtained the relevant consent and permission to use images submitted. You should follow your Trust's local policy on the use of patient data. An explanation should be given to the patient on how the images will be used. A copy of consent and permission should be kept by the entrant on file indefinitely.

OIA and Topcon reserve the right to publish any entry with suitable acknowledgement.

Submissions can not be returned.

All competition entrants must be OIA members. Non-member entrants will not be entered into the competition.

Closing Date: Friday, 22 October 2010.

Winners will be announced at the OIA Conference 2010.

Please return to:

Anne Bolton
Oxford Eye Hospital, The John Radcliffe Hospital, Headley Way,
Headington, Oxford OX3 9DU

Name

Job Title

Signed

Date

OIA Code

Categories

Please tick the relevant box:

Anterior Segment

Entries should be in colour and include the orbit, lids, sclera, cornea, anterior chamber, iris or lens.

Posterior Segment

Entries should be in colour and include vitreous, retina, disc and choroid. Multiple images composed as a single montage are allowed.

Fluorescein Angiography / Indocyanine Green Angiography

A sequence of up to 6 images can be presented or a single photographic montage of the retina, choroid or iris can also be submitted.

Optical Coherence Tomography

A single image of the macular, disc or periphery labelled with a brief explanation of the pathology depicted. Anterior segment OCT imaging can also be submitted.

Case Presentation

The report should consist of up to 10 images showing unusual or interesting pathology/ anatomy or how photographic skill was used to overcome problematic photographic management of the patient(s). A written report should support the photographic images. The report should include a case history, background, clinical findings, diagnosis and outcomes. Referencing other work is essential.

Artistic

One single image which uses ophthalmic imaging in a non-clinical way.